

## Foreign Bodies in the Gastro-Intestinal and Respiratory Tracts in Children: A Report on 14 Cases

ABDULRAHMAN A. ASHY, FRCS(1)

*Department of Surgery, Faculty of Medicine & Allied Sciences, King Abdulaziz  
University, Jeddah, Saudi Arabia*

**ABSTRACT.** The present study describes 14 cases of foreign bodies in the gastro-intestinal (13 cases) and respiratory (one case) tracts in children. Five of the cases were endoscoped. Three successful trails of removal of the foreign bodies were obtained (one bronchoscopically and two gastroscopically).

In addition, two foreign bodies among the 14 cases were intra-mural (one in the oesophagus and one in the duodenum) and could neither be seen by the endoscope nor during surgery. Oesophagotomy and duodenotomy to remove them had to be performed.

**Keywords:** Foreign bodies, GIT, Respiratory tract, Thoracotomy, Laprotomy.

### Introduction

The majority of the ingested foreign bodies (FB) require no medical or surgical intervention for removal, while those inhaled into the respiratory tract must be removed as soon as they are diagnosed. Prior to the era of modern endoscopy, patients required general anesthesia for removal of the ingested objects or the non-therapeutic ones introduced into the rectum<sup>[1]</sup>. Coins which are the most commonly FB ingested by children would pass spontaneously in most of the cases and are rarely retained, but sharp objects might pierce the wall of the gastro-intestinal tract (GIT) and lead to complications such as perforation, abscess formation or entero-vascular hemorrhage. Such objects need to be retrieved immediately after diagnosis. They might also be asymptomatic and discovered at a later stage when the patient starts to complain of dysphagia, abdominal pain or recurrent chest infection<sup>[2]</sup>. In the present study, thirteen cases of FB in the GIT

---

Correspondence & reprint requests to: Dr. A.A. Ashy, P.O. Box 6615, Jeddah 21452, Saudi Arabia.  
Accepted for publication after revision 19, July 1997. Received 10, December 1996.

and one case of the respiratory tract were all managed by the author. Successful conservative treatment was obtained in 9 cases while 3 cases were retrieved endoscopically and the other 2 had to be removed surgically.

### Patients and Methods

Between 1990-1994, 14 children (9 boys and 5 girls of 1 1/2 to 12 years of age) were seen in the emergency room and the out-patient department because of ingestion and inhalation of FB. Those who swallowed coins of different sizes confirmed by plain X-ray (9 children) were managed conservatively and given a mild laxative. It was successful and confirmed by observing the stools of the patients and taking a repeat plain X-ray of the abdomen. On the other hand, one child (a boy aged 2 years) swallowed a button battery and another child (a girl aged 7 years) swallowed a metal clip. Both FB were retrieved immediately after diagnosis by using the paediatric endoscope and the magnetic foreign body extractor to avoid the possibility of perforation. The cases were done under general anaesthesia. The other three children (3,5, and 7 years of age) were seen in the out-patient clinic because of repeated vomiting and failure to thrive, recurrent chest infection and cough for a few months, and recurrent abdominal pain with occasional vomiting respectively. Plain X-ray of the chest of the first child (3 year old boy) showed a metallic FB in the form of a ring (Fig. 1). It was stuck at the junction between the

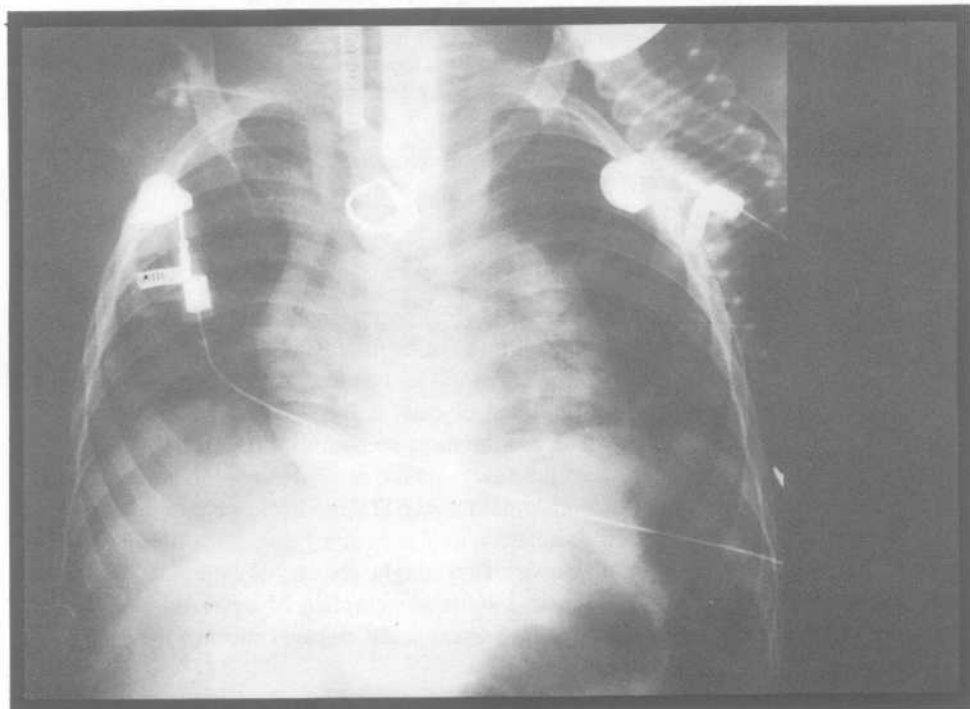


FIG. 1. Plain x-ray of the chest showing the ring in the wall of the oesophagus. The endotracheal tube and the rigid oesophagoscope are also seen.

upper and middle thirds of the oesophagus<sup>[3,4]</sup>. The history from parents was very unhelpful. The second child (5 year old girl) had been coughing for two months with chest infection not responding to medical treatment. She had a decreased air entry to the left lower lobe of the lung. Chest X-ray showed unresolved pneumonia with partial collapse of the left lower lobe of the lung possibly due to the presence of a bronchial FB. The third child (7 year old boy) gave a history of recurrent abdominal pain with occasional vomiting. Plain abdominal X-ray showed a hairpin in the region of the second part of the duodenum (Fig. 2). All the three children were admitted to the hospital for a trial of

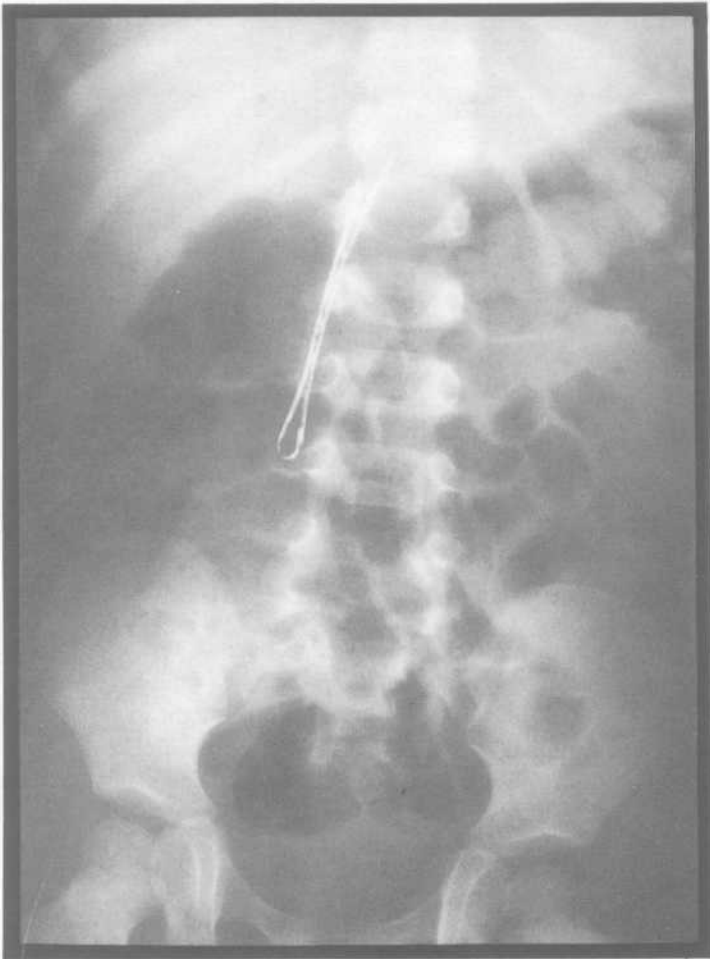


FIG. 2. Plain x-ray of the abdomen showing the hair-pin in the wall of the second part of the duodenum.

endoscopic removal of the FB using procedures described previously<sup>[5,6]</sup>. Only the girl with the FB in the left bronchus has a successful bronchoscopic removal of the peanut which was very firmly adherent to the wall of the bronchus and was taken out piecemeal (Fig. 3). The procedure was done under general anesthesia using the rigid bron-

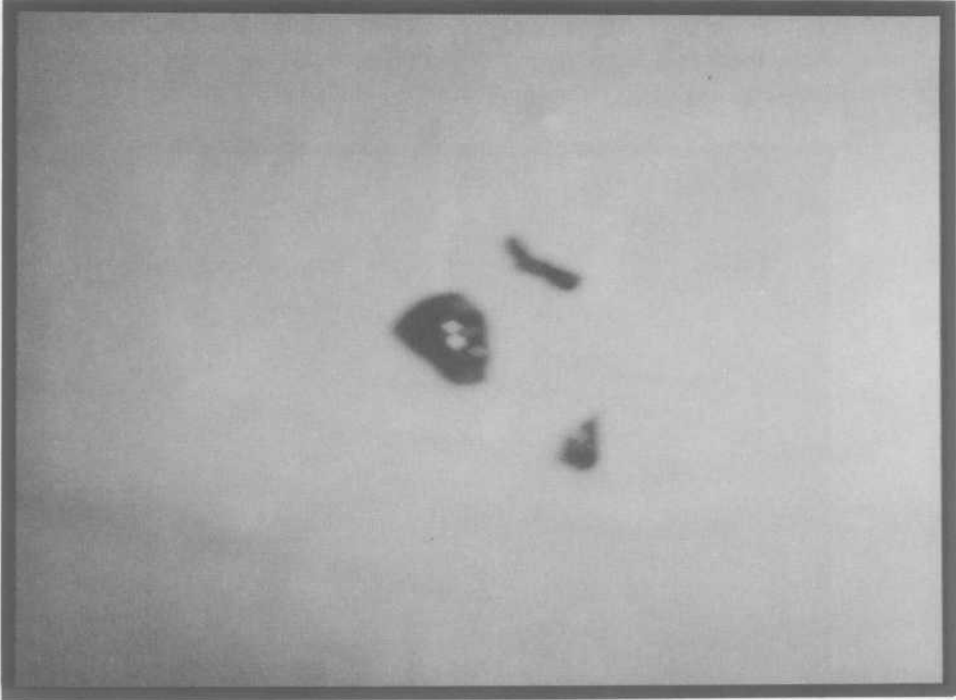


FIG. 3. Showing the rusty peanut after extraction piecemeal from the left bronchus.

choscope after a consent from the parents was obtained. Upon removal of the peanut, immediate return of good air entry to the left lower lobe of the lung was noticed by the anesthesiologist. The child stayed in hospital for overnight and post-bronchoscopic chest X-ray was done and confirmed the inflation of the lobe. The patient was given a course of broad spectrum antibiotic with cough medicine and discharged home the following day after she had made an uneventful recovery. She was followed-up in the clinic one week later with no further chest manifestation. The other two boys (3 and 7 years of age) had endoscopic trials to see and remove the metallic FB which were unsuccessful even under fluoroscopic control because they were embedded inside the wall of the alimentary tract. Consent from the parents were taken for the right thoracotomy (4<sup>th</sup> intercostal space and laparotomy), respectively (Fig. 4).

The dark and rusty ring was found in the cicatrix of the oesophageal wall and removed through a longitudinal incision of the wall which was then repaired without causing stenosis of the oesophageal lumen (Fig. 5). Post-operatively underwater seal drain was left for one week. Gastrografin swallow was done before the removal of the drain and showed a good flow without leakage. The child was discharged home on the

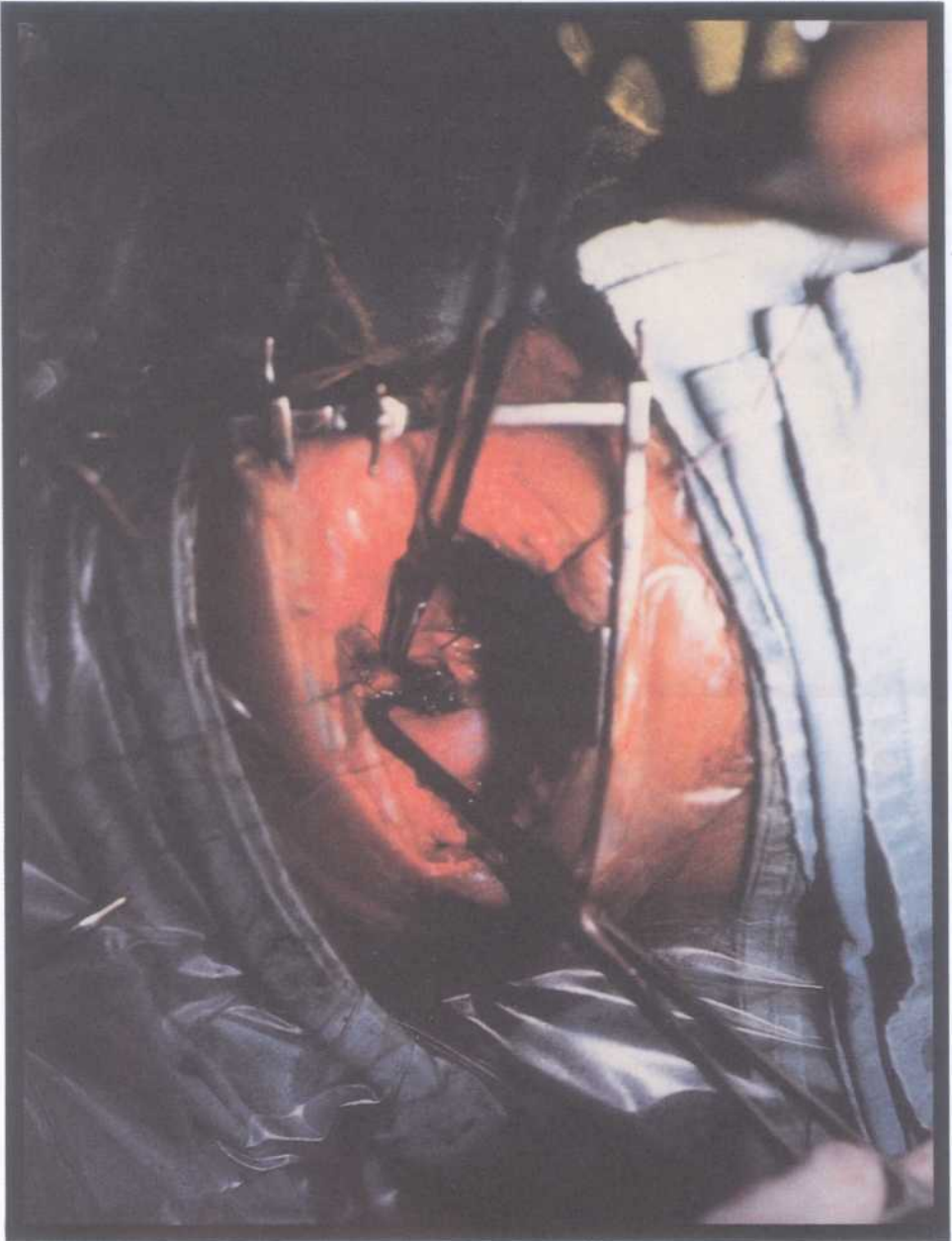

FIG. 4. The rusty ring is shown during extraction from the oesophagus through right thoracotomy.




FIG. 5. Showing the rusty ring after removal.

following day and reviewed in the clinic without showing any post-operative complications. Regular follow-up was very satisfactory and the child grew up normally afterwards. The third child (7 year old boy) had a laparotomy and duodenotomy after kocherization. The hairpin was also found in the cicatrix of the duodenal wall in its second part away from the duodenal papillae according to the procedures described previously<sup>[7,8]</sup>. It was extracted successfully and was also found rusty (Fig. 6). The duodenum was closed with size 2/0 Vicryl without obstruction to the lumen. A drain was left beside the duodenotomy and removed 3 days later after the gastrografin meal study showed a good flow and no leakage. The patient was given oral fluids followed by regular diet and was discharged home on the sixth post-operative day. He made an uneventful recovery. Regular check-up in the clinic was again very satisfactory.

### Results

. Nine out of 13 gastrointestinal FB passed spontaneously, per anus. The remaining 4 were endoscoped with successful removal of the FB in 2 of them while in the other 2 patients the FBs could not be visualized as they were intramural, but they were removed surgically through right thoracotomy and laparotomy, respectively. The 14th patient who inhaled the peanut had successful bronchoscopic removal of the peanut from the left bronchus. Non of the patients had any endoscopic or post-operative complications.



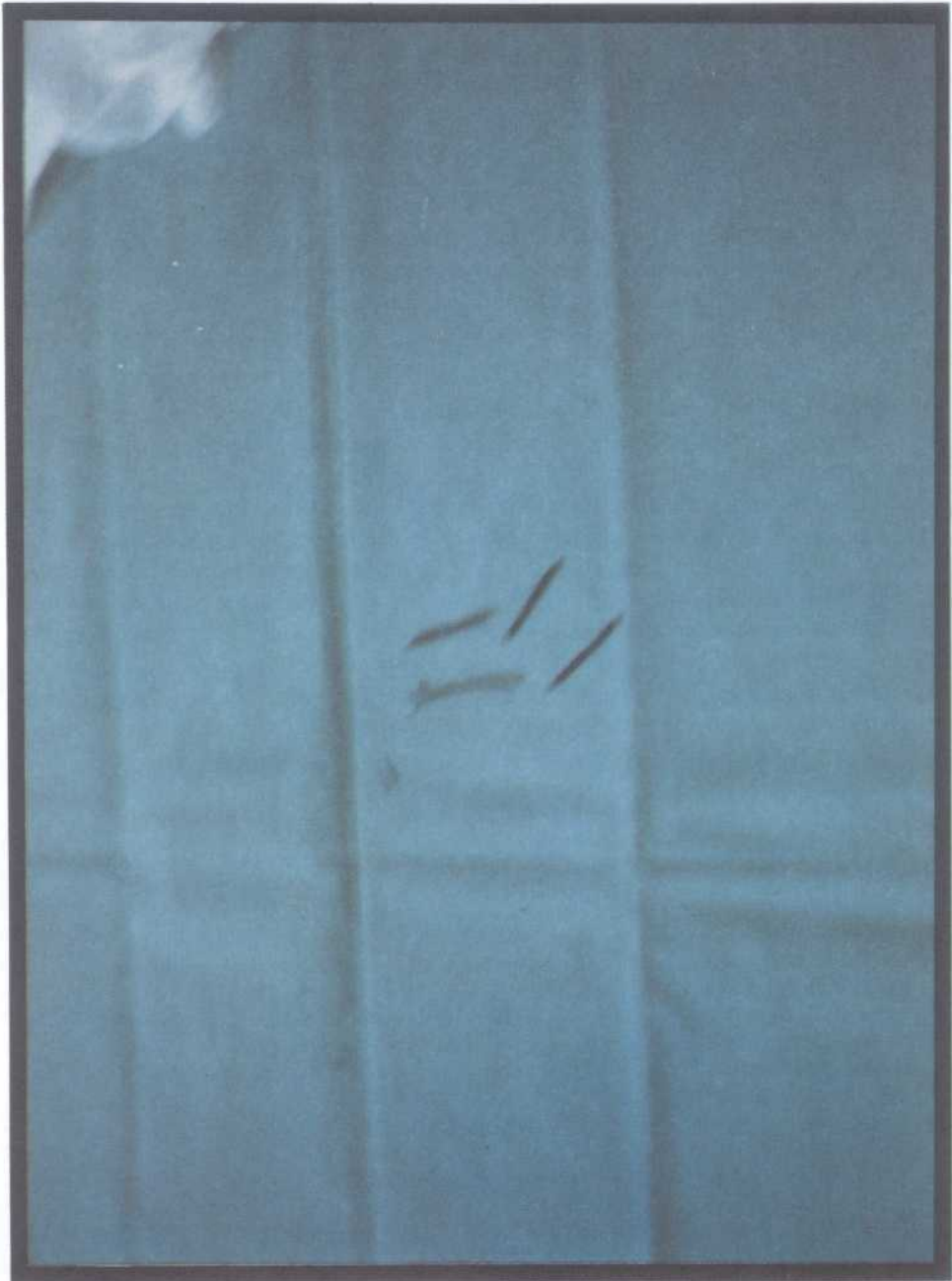


FIG . 6. Showing the rusty hair-pin after removal piecemeal.

### Discussion

Although most FB pass through the GIT without difficulty; sharp, pointed and elongated FB are associated with a greater risk of perforation, vascular penetration and other complications<sup>[9-11]</sup>. Artificial perforation might occur during the endoscopic removal of the FB from the oesophagus<sup>[12-14]</sup>. The penetration might lead to migration of the FB from the gut to the outside<sup>[15,16]</sup>. The FB can also be found retained in the stomach after pyloromyotomy in children due to the disturbed pyloric function after such surgery<sup>[17-19]</sup>. The cause of the presence of FB in the alimentary or respiratory tract in children is usually incidental. Coins are more frequently ingested, while peanuts account for more than 80% of the inhaled bronchial FB<sup>[20]</sup>. Some of the FB are radio-opaque and can be seen on plain X-ray while others need special techniques or endoscopy.

In children the history should be obtained carefully from the parents or observers but this again might not be complete and helpful in some cases. Dysphagia, recurrent abdominal pain or recurrent chest infection in a little child might give a clue to the diagnosis. The use of the metal detector as a new modality to detect metallic FB is as useful as the plain X-ray which is considered as the golden tool<sup>[21]</sup>. In some of the reports, conservative management was successful in 93% of cases while 7% needed operative removal<sup>[22-23]</sup>. The FB containing mercury or lead or those which are pointed and sharp should be extracted as soon as possible to avoid complications<sup>[24,25]</sup>. The FB in the bronchial tree should be removed bronchoscopically as soon as they are diagnosed, while the impacted FB in the gut might need surgical removal if the endoscopy trial is failed. The intra-mural FB with no doubt should be removed surgically through thoracotomy or laparotomy<sup>[26,27]</sup>.

### References

- [1] Lyons MF, Tsuchida Am. Foreign bodies of the gastro-intestinal tract. *Med Clin N Am* 1993; **77**: 1101-1114.
- [2] Brady P. Esophageal foreign bodies. *Gastroenterol Clin N Am* 1991; **20**:161-701.
- [3] Weissburg D. Foreign bodies in the gastro-intestinal tract. *S Afr J Surg* 1991; **4**: 150-153
- [4] McComas BC, Van-miles P, Katz BE. Successful salvage of an 8-month child with an aoesophageal fistula. *J Pediatr Surg* 1991; **26**: 1394-1395.
- [5] Celestino A, Castillo T, Contardo C, Frisancho O. Fiber endoscopy in the extraction of foreign bodies from the Gastro-intestinal tract. *Rev gastroentrol* 1992; **12**: 53-56.
- [6] Mangal BD, Mangal Y, Pandey RP. Retrieval of foreign body from upper gastro-intestinal tract by flexible fiber optic endoscope. *J Assoc Physicians India* 1993; **4**: 11-13.
- [7] Munoz NA, Takehara H, Hashimoto T, Yoshida K, Komi N. An unusual gastric foreign body. *Acta Pediatr Jpn* 1991; **33**: 492-495.
- [8] Roy S, Barjal SS, Phadke RV, Choudhuri G. GIT foreign bodies: A case report. *Aust Radiol* 1992; **36**:80-82.
- [9] Scher RL, Tegtmeyer CJ, Mclean WC. Vascular injury following foreign body perforation of the esophagus. *Ann Otol Rinol Laryngol* 1990; **99**: 698-702.
- [10] Benkert G, Gutfreund C. Perforation of the duodenum caused by a swallowed table knife. A case report. *Fortsechr Med* 1991; **109**: 163-164.
- [11] Ben, Rejeb A, Gammoudi A, Ben, Alaya M. Intestinal perforation by a fish bone. *Ann Chir* 1993; **47**: 68-70.
- [12] Olah T, Horvath Op, Szendrenyi V, Selmecezi A. A endoscopic and surgical removal of foreign



- bodies from the upper gastro-intestinal tract. *Orv Hetil* 1993; **134**: 345-348.
- [13] **Bertoni G, Pacchione D, Conigliaro R, Sassatelli R, Pedrazzoli C, Bedogni G.** Endoscopic protector hood for safe removal of sharp pointed gastro-oesophageal foreign bodies. *Surg Endosc* 1992; **6**: 255-258.
- [14] **Bertoni G, Pacchione D, Sassatelli R, Ricci E, Mortilla MG, Gumina C.** A new protector device for safe endoscopic removal of sharp gastro-oesophageal foreign bodies infants. *J Pediatr-Gastroenterol Nutr* 1993; **16**: 393-396.
- [15] **Burton DM, Stith JA.** Extraluminal esophageal coin erosion in children. A case report review. *In J Peadiatr Otorhinolaryngol* 1992 **23**: 187-194.
- [16] **Klyver H, Eliassen EK.** Migration of suture material from the abdominal cicatrix to the urinary tract. *Ugeskr Laeger* 1992; **154**: 2764-2765.
- [17] **Wheeler WE, Hanks J, Raman VK.** Primary aortoenteric fistulas 1992; **58**: 53-54.
- [18] **Risher WH, McKinnon WM.** Foreign body in gastro-intestinal tract. Intraluminal migration of laparotomy sponge. *South Med J* 1991 **84**: 1042-5.
- [19] **Stringer MD, Kiely EM, Drake DP.** Gastric retention of swallowed coins after pyloromyotomy. *Br J Clin Pract* 1991; **45** 1: 66-67.
- [20] **Murata Y, Nakagawa Y, Ueda M, Takakura I.** Accidents in childhood. Review of cases in the emergency room and hospitalized cases. *Tokai J Exp Clin Med* 1992; **3** 4: 121-127.
- [21] **Arena L, Baker SR.** Use of a metal detector to identify ingested metallic foreign bodies. *Am J Roentgenol* 1990; **155** 4: 803-804.
- [22] **Clarkston WK.** Gastrointestinal foreign bodies. When to remove them, when to watch and wait. *Postgrad Med* 1992; **46** 8: 51-59.
- [23] **Krustanov P.** Ingested foreign bodies. *Khirurgia Sofiia* 1991; **44** 4: 10-13.
- [24] **Bass DH, Millar AJ.** Mercury absorption following button battery ingestion. *J Pediatr Surg* 1992; **27**: 1541-1542.
- [25] **Wiley JF, Henritec FM, Selbst SM.** Blood lead levels in children with foreign bodies. *Pediatrics* 1992; **89** (4 Pt 1): 593-6.
- [26] **Olak J, Jeyasingham K.** Cervical esophageal diverticulum associated with an impacted denture. A case report. *Surgery* 1991; **34** 36: 614-617.
- [27] **Cooke LD, Baxter PW.** Accidental impaction of partial dental prosthesis in the upper gastrointestinal tract. *Br Dent J* 1992; **172**: 541-542.

## الأجسام الغريبة داخل الجهاز الهضمي عند الأطفال

عبد الرحمن آشي

قسم الجراحة العامة ، كلية الطب والعلوم الطبية ، جامعة الملك عبد العزيز  
جدة - المملكة العربية السعودية

المستخلص . إن ابتلاع الأجسام الغريبة غير المقصود عند الأطفال غالباً ما يحدث خلال العام الأول من حياة الطفل ، وإن من أكثر الأجسام الغريبة والتي توجد في معدة وأمعاء الطفل هي قطع النقود المعدنية والتي في الغالب تخرج مع البراز ولا تحتاج إلى تدخل جراحي أو إجراء عملية منظار لاستخراجها . أما الأجسام الغريبة التي لها رؤوس حادة أو مدببة ، فهذه قد تخترق جدار الجهاز الهضمي وتسبب به ثقباً أو تجمعاً صديدياً أو ناصوراً حول مكان توقف الجسم الغريب ، كما أن هذا الجسم الغريب قد يكمن في مكانه مدة طويلة من الزمن يحتاج بعدها لعملية جراحية لاستئصاله . أما بالنسبة للأجسام الغريبة التي تدخل إلى الجهاز التنفسي ، فهذه تسبب التهاباً مزمناً في الرئتين والشعب الهوائية عند الأطفال . وفي هذه الدراسة المستقبلية سنناقش ثلاثة عشرة حالة أجسام غريبة في الجهاز الهضمي وحالة واحدة في الجهاز التنفسي عند الأطفال مع مراجعة للأبحاث المنشورة في هذا المجال .