

Cystic Lymphangioma of Spermatic Cord: A Case Report and Literature Review

Yasir S. Jamal FRCS(I), FICS, **Abdel-Rahman R. E. Abdel-Halim**,
Sabah S. Moshref¹ FRSC(I), **Mazen O. Kurdi** FRCS(I),
and **Husain I. Sandugji**, CABS

*Department of Surgery, Division of Pediatric Surgery
and ¹Division of Plastic Surgery, Faculty of Medicine
King Abdulaziz University, Jeddah, Saudi Arabia*

ysmsj@yahoo.com

Abstract. Lymphangiomas are congenital malformations of the lymphatic system. These tumors usually occur in the neck and axilla, occasionally in the mediastinum, retro peritoneum, and thigh. The scrotum and perineum are the least frequent sites. Although, spermatic cord lymphangiomas are very rare, they have to be considered in the differential diagnosis of the atypical cystic scrotal swellings in order to avoid misdiagnosis, improper treatment and recurrence. We report a 3-year old boy with cystic lymphangioma of the spermatic cord extending from inguinal canal down to involve the tunica vaginalis but not the scrotal wall, it was discovered intra-operatively in inguinal exploration for incompletely reducible inguinal swelling which found to be inguinal hernia in associated with the cystic lymphangioma of the spermatic cord so Lt inguinal herniotomy and complete surgical excision of the lymphangioma of the spermatic cord including the tunica vaginalis were done. Post operative follow-up for 3 years clinically and ultrasonographically indicated no recurrence. With presenting this case, we will review the literature on this subject.

Keywords: Scrotal Swelling, Spermatic cord, Lymphangioma, Cystic hyroma, Child-case report, Literature review.

Introduction

Lymphangioma is a rare hamartoma, a benign tumor caused by congenital malformation of the lymphatic system, usually occurs in the neck and axilla, occasionally in the mediastinum, retro-peritoneum, and thigh. The scrotum and perineum are the least frequent sites^[1]. The actual incidence of lymphatic malformations (LM) is unknown, but it is believed to exceed the original estimate of 6.3% of all malformations^[2]. Lymphatic malformations are varied group of ill defined vascular anomalies which share common histology and embryology; they are congenital defects of the lymphatic system. The pathogenesis based on what we know of normal lymphatic embryogenesis, it is a result of sequestration of tissue of embryonic lymphatic sac which in turn results in failure to establish connection with lymphatic stream at six to seven weeks of fetal life, which results in dilated endothelium and cysts formation. It is usually present as wide spectrum of deformities including lymphangioma circumscriptum, cavernous lymphangioma, cystic hygroma, hemangio-lymphangioma and lymphangioma diffusum^[3].

Lymphangioma is classified as simple, cavernous, or cystic by size of the dilated lymphatic spaces within the tumor. Most cases present as a soft, cystic, slowly enlarging swelling^[4]. It was suggested that the various morphological types of LM can be explained by their anatomical location *e.g.*, Lesion occurring in areas with distinct tissue planes and loose areolar tissue (*e.g.*, neck, axilla, and mediastinum, scrotum) are able to expand and form cystic structure, Conversely LM in the lips, cheek and tongue are bound by a more restrictive organization of tissue and will present as compact lesion^[5].

Histopathologically cystic lymphangioma is formed of cystic spaces which are unilocular, multilocular and diffuse. All cysts are lined with single layer of endothelium which contain fluids (acidophilic, rich in protein). If there is blood it means recent hemorrhage or combined lymphaticovenous malformation. These cysts are of different sizes.

We present cystic lymphangioma of spermatic cord associated with Lt. inguinal hernia in a 3-years-old boy who presented having left inguinoscrotal mass with incomplete reducibility.

Case Report

A 3-year-old Saudi boy presented with a painless left inguinoscrotal mass which was increasing with straining and decreasing in size with lying down. There was no history of previous trauma to the region but with retrospective positive family history of cystic hygroma of neck and Lymphangioma circumscriptum of tongue in his cousin. On examination, there was left sided incomplete reducible inguinal swelling; however, spermatic cord felt significantly thickened when the hernia was reduced (Fig. 1). Testes were normal bilaterally. He was otherwise well, and there was no palpable inguinal adenopathy or similar lesions elsewhere. The patient came with an ultrasound report suggesting a picture of multiple lipomas of the spermatic cord. No further imaging studies were performed in our hospital and through lower inguinal transverse crease incision the area was explored. Hernial sac was found, dissected, transfixed and excised easily. There were multiple cystic lesions of varying sizes cysts between cord structures filled with clear fluid (Fig. 2) extending from inguinal canal down to involve the tunica vaginalis but not to the scrotal wall (Fig. 3). The mass was excised in its entirety including the tunica vaginalis (Fig. 4).

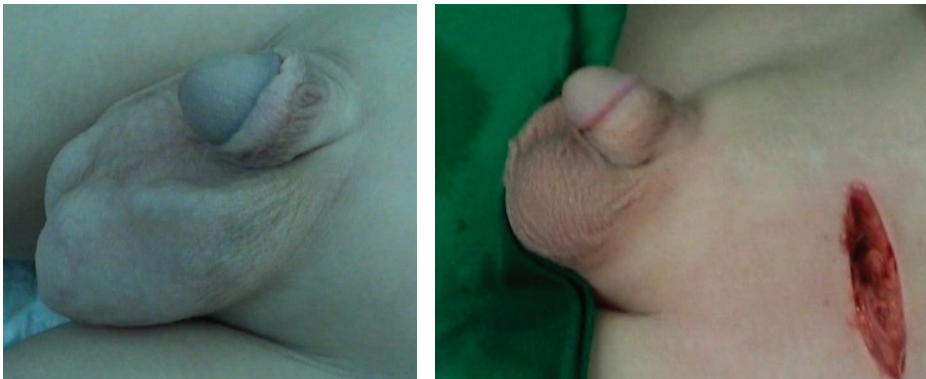

Fig. 1. Photograph for the Lt groin - (Left) after reduction of the Lt inguinal hernia showing the residual lobulated swelling; (Right) post-operative view showing the normal appearance of the Lt hemiscrotum.

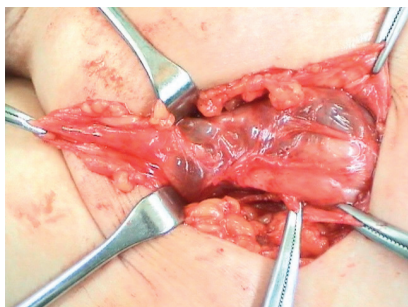


Fig. 2. Intra-operative photograph showing multicystic mass of the spermatic cord extending through inguinal ring.

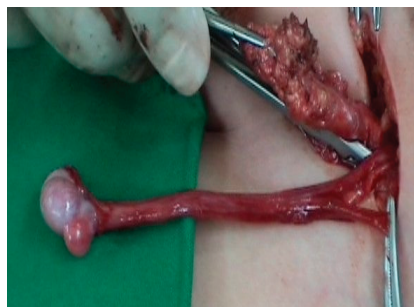

Fig. 3. Intra-operative photograph after separation of the mass from cord structures protruding from the inguinal ring but no further intra abdominal extension.

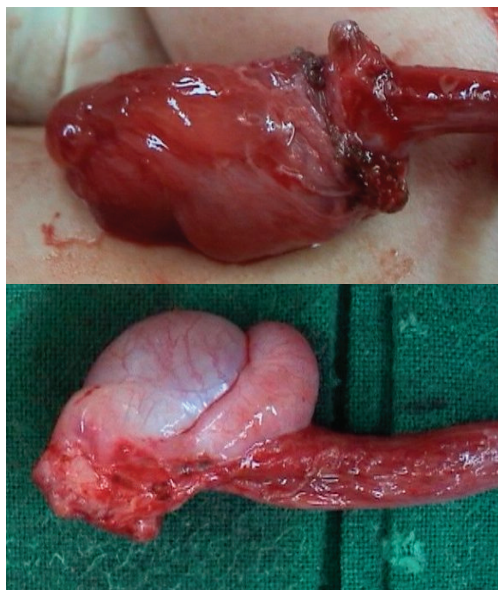

Fig. 4. Intra-operative photograph after separation of the mass from cord structures. (upper) Showing the involvement the tunica vaginalis with the cysts; (lower) excised tunica vaginalis with the cysts.

Histopathologically, it was a soft multicystic grayish tissue measuring $3 \times 3 \times 1$ cm. Sections revealed congested fibrofatty tissue infiltrated with multiple dilated spaces lined by endothelial cells and filled with lymph and scattered lymphocytes. A picture consistent with cystic lymphangioma.

Two weeks postoperatively, abdominopelvic ultrasound was done to make sure no other abdominal or pelvic lymphatic malformations which were normal. Patient has been followed up clinically and ultrasonography over the last 3 years and remains well, with no evidence of recurrence.

Discussion and Literature Review

Lymphangioma is a benign tumor of the lymphatic system classified as simple, cavernous, or cystic by the size of the dilated lymphatic spaces within the tumor. Most cases present as a progressively slowly enlarging soft mass. 95% of these lesions occur in the neck and/or axilla, other site less frequently affected but scrotal presentation is rare but reported^[4,6-8].

Intra-scrotal cystic lymphangioma which involve the spermatic cord or epididymis or tunica vaginalis should be differentiated from the lymphangioma that involving the scrotal wall in the form of lymphangioma circumscriptum as the surgical approach is different, we believe that the intra-scrotal cystic lymphangioma is localized retroperitoneal lymphangioma which migrate with tunica vaginalis during the descent of the retroperitoneal testis to its final destination as the lymphangioma remain within the covering of the cord and does not extend to the scrotal wall but can remain localized *i.e.*, epididymis or spread over along the cord from the inguinal ring to tunica vaginalis as in our case, this limitation precludes the need of any scrotal excision unlike the scrotal lymphangioma circumscriptum where scrotal excision is indicated^[9,10].

Intra-scrotal cystic lymphangioma is a rare intra-scrotal mass, 11 cases of cystic lymphangioma of spermatic cord were reported up to 1996 by Jung *et al.*, not including their case^[11]. Hurwitz *et al.* reviewed the literature on scrotal lymphangioma and estimated that around 40 cases have been reported. However, cutaneous scrotal lymphangioma were included. Additionally, they reported 7 more cases with scrotal lymphangioma treated in 5 institutions over a 12 years duration^[6]. We reviewed the literature up to date of our case (2008) and found 7 more cases^[1,12-17]. Cases of lymphangioma circumscriptum were excluded. Out of the seven cases, 4 were in pediatric patients with a presenting age varying from 1 day to 7 years^[1,14-16]. Three patients presented with

painful scrotal swelling; only one of them following trauma to the scrotum^[1,12,14]. Clinically, two cases were diagnosed as hydrocele, one case as varicocele and torsion was suspected in a single case^[14,17].

Intra-scrotal cystic lymphangioma can be mistaken for other common and uncommon scrotal extra-testicular cystic conditions such as hydrocele, varicocele, hematocele inguinal hernia, epididymal cyst, spermatocele, lipoma of the spermatic cord, dermoid of the spermatic cord and Hydatid of Morgagni^[18-21].

Ultrasound is the initial choice of diagnostic imaging but CT and MRI are more informative of the important features, the extent of the lymphangioma and its relationship to adjacent soft tissue, muscle and vascular structure as the proper evaluation of the extent of the lesion is important in planning the appropriate approach for the mandatory complete surgical excision to avoid the recurrence commonly associated with incomplete excision. Diagnostic aspiration for fluid analysis used to reach the diagnosis in primary lesions and in recurrent cases, but the final diagnosis depends on the histopathological confirmation^[6,22,23].

Complete surgical excision was the gold standard treatment modality^[6,17,21,23]. However, OK-432 was used exclusively by Uchida *et al.* in his case^[15]. Ratan *et al.*, unfortunately, needed to do orchidectomy in his case where the lesion was inseparable from cord structures^[16]. In an adult case complete orchidectomy was indicated due to recurrence after excision of scrotal lymphangioma with partial orchidectomy. The recurrence in such cases with longstanding lesion can be expected due to the infection and fibrosis which make the lesion inseparable with incomplete excision^[17]. Recurrence was common in the cases with incomplete excision but no recurrence was noted in any case after total excision^[6,17,22,23].

In our case report, age of presentation was as the mean age mentioned in most of the previous case studies. The uncommon presentation we had in our case was the presence of the inguinal hernia which wasn't completely reducible. This presentation contributed in diverting us from suspecting the full diagnosis preoperatively. The incomplete reducibility was assumed to be either incarcerated omentum or lipoma of the cord as indicated in the ultrasound report brought with the patient but intra-operatively was noted to be due to a multicystic inguinoscrotal mass lesion along the spermatic cord down to involve the

tunica vaginalis. Histopathological examination confirmed the diagnosis of cystic lymphangioma. Similar case of cystic scrotal lymphangioma associated with inguinal hernia has been reported but the lymphangioma was limited to the epididymis and not involving the spermatic cord up to inguinal canal as in our case^[24].

Conclusion

Scrotal cystic lymphangioma is a rare lesion that should be included in the differential diagnosis of unusual cystic scrotal masses. Moreover, a cystic or septate scrotal mass discovered intra-operatively should not be dismissed as a complex hydrocele, since cystic lymphangioma predictably recur if incompletely resected. So proper preoperative diagnosis of the scrotal lymphangioma and its extent utilizing US, CT and MRI is essential for planning of appropriate approach for the mandatory complete surgical excision to prevent recurrence.

References

- [1] **Hamada Y, Yagi K, Tanano A, Kato Y, Takada K, Sato M, Hioki K.** Cystic lymphangioma of the scrotum. *Pediatr Surg Int* 1998; **13**(5-6): 442-444.
- [2] **Fischer A, Mitchell S, Tufaro A.** *Lymphatic and Venous Vascular Malformations: principles and practice of pediatric surgery* 2005; pp: 1691-1699.
- [3] **Kennedy TL.** Cystic hygroma–lymphangioma: a rare and still unclear entity. *Laryngoscope* 1989; **99**(10 Pt 2 Supple 49): 1-10.
- [4] **Singh S, Baboo ML, Pathak IC.** Cystic lymphangioma in children: report of 32 cases including lesions at rare sites. *Surgery* 1971; **69**(6): 947-951.
- [5] **Bill AH Jr, Sumner DS.** A unified concept of lymphangioma and cystic hygroma. *Surg Gynecol Obstet* 1965; **120**: 79–86.
- [6] **Hurwitz RS, Shapiro E, Hulbert WC, Diamond DA, Casale AJ, Rink RC.** Scrotal cystic lymphangioma: the misdiagnosed scrotal mass. *J Urol* 1997; **158**(3 Pt 2): 1182-1185.
- [7] **Pandit SK, Rattan KN, Budhiraja S, Solanki RS.** Cystic lymphangioma with special reference to rare sites. *Indian J Pediatr* 2000; **67**(5): 339–341.
- [8] **Vázquez Rueda F, Moñiz Mora MV, Salas Molina J, Pizarro de Celis FJ, Ocaña Losa JM.** [Lymphangioma of the spermatic cord] *Actas Urol Esp* 2000; **24**(3): 260-261.
- [9] **Vikicevic J, Milobratovic D, Vukadinovic V, Golubovic Z, Krstic Z.** Lymphangioma scrota. *Pediatr Dermatol* 2007; **24**(6): 654-656.
- [10] **Latifoğlu O, Yavuzer R, Demir Y, Ayhan S, Yenidünya S, Atabay K.** Surgical management of penoscrotal lymphangioma circumscriptum. *Plast Reconstr Surg* 1999; **103**(1): 175-178.
- [11] **Jung JL, Abouelfadel Z, Straub P.** [Cystic lymphangioma of the spermatic cord. Report of a new case] *Prog Urol* 1996; **6**(6): 948-949.

- [12] **Napier-Hemy RD, McMahon RF, Payne SR.** The acute scrotum: beware the non-scrotal cause. *BJU Int* 1999; **83**(7): 878.
- [13] **Kingsly KA, Sant GR.** Images in clinical urology. Scrotal lymphangioma in an adult. *Urology* 1999; **53**(4): 820-821.
- [14] **Mhoon JM, Redman JF, Siebert JJ.** Scrotal enlargement in boys with a history of scrotal trauma: two unusual findings. *South Med J* 2002; **95**(2): 251-252.
- [15] **Uchida K, Inoue M, Araki T, Miki C, Kusunoki M.** Huge scrotal, flank, and retroperitoneal lymphangioma successfully treated by OK-432 sclerotherapy. *Urology* 2002; **60**(6): 1112.
- [16] **Ratan SK, Rattan KN, Sehgal T, Maggu S.** Spermatic cord lymphangioma in a 7-year-old child masquerading as a hydrocele. *BJU Int* 2003; **91**(Suppl 3): e33.
- [17] **Grossgold ET, Kusuda L.** Scrotal lymphangioma in an adult. *Urology* 2007; **70**(3): 590.e1-2.
- [18] **Rajagopalan S.** An unusual pediatric scrotal lump. *Indian J Pediatr* 2005; **72**(9): 801.
- [19] **Abantanga FA.** Groin and scrotal swellings in children aged 5 years and below: a review of 535 cases. *Pediatr Surg Int* 2003; **19**(6): 446-450.
- [20] **Rattan KN, Kumar S, Gahlawat S, et al.** Dermoid cyst of spermatic cord: an uncommon presentation in a child. *Ann Diagnostic Pediatr Pathol* 2008; **12**(1-2): 37-90.
- [21] **Parra Muntaner L, López Pacios JC, Sánchez Merino JM, Bouso Montero M, Gómez Cisneros SC, Piñeiro Fernández MC, García Alonso J.** [Lipoma of spermatic cord; report of a case] *Arch Esp Urol* 2000; **53**(9): 843-845.
- [22] **Ansari A, Ansari HAK, Banerjee B.** Unusual scrotal mass and review of scrotal imaging. *Radiography* 2009; **15**: 91-93.
- [23] **Lin E, Yang S.** Cystic lymphangioma in the pelvic cavity. *JTUA* 2003; **14**(2): 92-94.
- [24] **Pai KK, Roy D.** Lymphangioma of epididymis: An extremely rare cause of scrotal swelling. *Indian J Urol* 2006; **22**: 275-276.

ورم كيسي لمفاوي في الحبل المنوي: تقرير حالة ومراجعة الأدبيات الطبية

ياسر صالح جمال ، وعبدالرحمن ربيع عبدالحليم ، وصباح صالح مشرف ،
و مازن عمر كردي، وحسين أبراهيم صندوقي
قسم الجراحة وحدة جراحة الأطفال، و'وحدة جراحة التجميل، كلية الطب ،
جامعة الملك عبدالعزيز، جدة - المملكة العربية السعودية

المستخلص. تعتبر الأورام اللمفاوية من العيوب الخلقية للجهاز اللمفاوي والتي غالبا ما تتكون في الرقبة، والإبط، والمنصف، وخلف البريتون، والفخذ، ويندر حدوثها بكيس الصفن والعجان، ومن النادر جدا تكونها في الحبل المنوي، وعلى الرغم من ذلك إلا أنه لا بد من أخذها في الاعتبار كأحد التشخيصات المحتملة الحدوث في كيس الصفن، لأن تمييزها وتشخيصها هام في العلاج وتجنب الارتجاج. نقدم في هذا التقرير حالة طفل عمره ٣ سنوات يعاني من ورم ليمفاوي كيسي بالحبل المنوي يمتد من القناة الأربية وحتى كيس الصفن، إلا أنه غير ممتد لجدار كيس الصفن، وقد تم تشخيصه أثناء العمل الجراحي لاستكشاف المنطقة الأربية لوجود كتلة أربية غير كاملة الارتجاج، حيث اتضح وجود فتق أربي مع الورم اللمفاوي، وقد تم إغلاق الفتق، وتم استئصال الورم اللمفاوي بالكامل، وقد تمت متابعة المريض سريريا، وبالأشعة الصوتية على مدى ٣ سنوات، ومع تقديم هذه الحالة نراجع الأدبيات الطبية لهذا الموضوع.